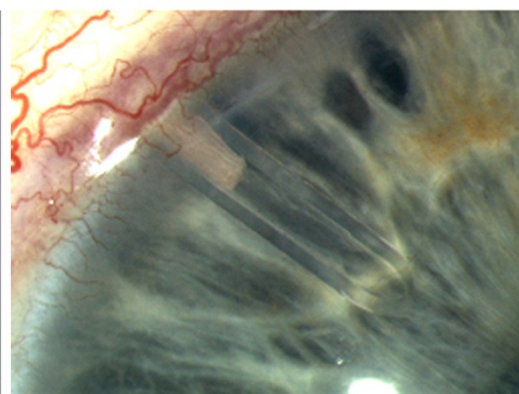
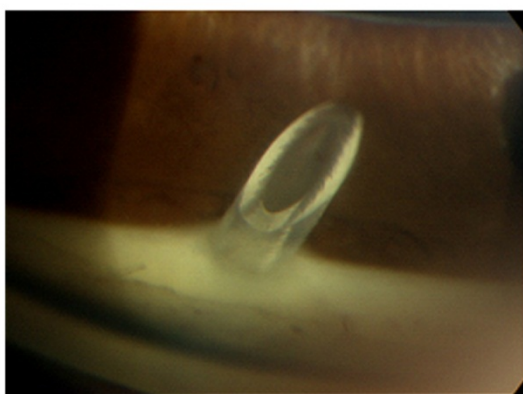
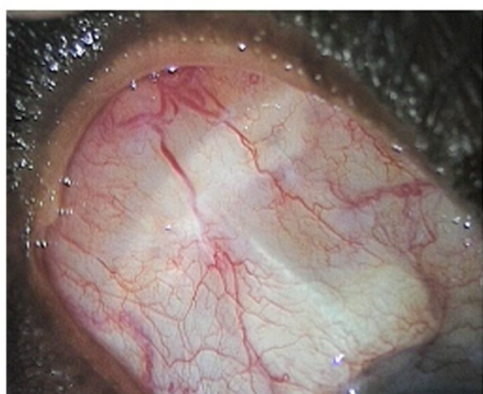


# AQUEOUS SHUNT IMPLANTATION

*Information for Patients*



by Keith Barton

## Contents

	<b>Page</b>
1. Introduction – What are aqueous shunts and what do they do?	3
2. How will the shunt affect the external appearance of the eye?	4
3. Medication prior to surgery	6
4. The surgery itself	6
5. After surgery – postoperative care	8
6. Success rates and complications	11
7. References	13
8. Glossary	14
9. Acknowledgements	15
10. Disclaimer	15

## 1. Introduction – What are aqueous shunts and what do they do?

Aqueous shunts are devices that are used to reduce the eye pressure (intraocular pressure) in glaucoma by draining the fluid (aqueous humor) from inside the eye to a small blister or *bleb* behind the eyelid. Reducing the pressure on the optic nerve in this manner prevents further damage and further loss of vision in glaucoma.

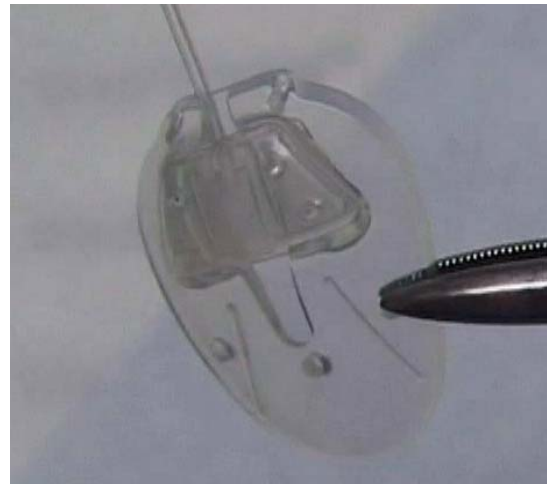
Please note that control of the eye pressure with an aqueous shunt will not restore vision already lost from glaucoma.

The aqueous humor is a fluid inside the eye and is not related to the tears. Watering of the eye is caused by tears, not aqueous humor. The aqueous shunt reduces the eye pressure by draining aqueous humor.

Aqueous shunts have various other names such as tube implants, glaucoma tube shunts, glaucoma drainage devices, glaucoma drainage implants and setons. These names all refer to the same thing. Although there are many types of shunt available, two brands are in common use today and they function in a similar fashion. These are called the *Ahmed Glaucoma Valve* and the *Baerveldt Glaucoma Implant*. In certain circumstances a third type, known as the *Molteno Implant*, might also be used.



**Baerveldt 350 Implant**



**Ahmed Glaucoma Valve**

These shunts are made up of a small silicone tube (less than 1 mm in diameter) attached to a plate. The tube takes the aqueous humor from inside the eye and drains it to the plate which sits on the white of the eye (sclera). The plate sits under the skin of the eye (conjunctiva), behind the eyelid.

Although all shunts perform approximately the same function, there are important differences that affect the eye pressure in the first few weeks after surgery and other differences that influence the healing of the eye around the shunt and the long-term eye pressure.

The *Ahmed Glaucoma Valve* contains a type of valve that helps to prevent very low eye pressure during the first few weeks after surgery. The *Baerveldt* and *Molteno* implants do not contain valves but do have other advantages.

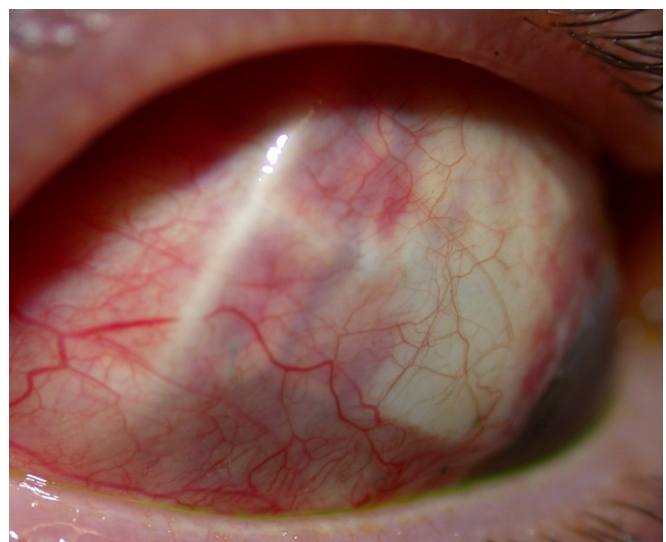
Because the *Baerveldt* and *Molteno* implants have no valve, they must be blocked with a stitch that is either tied around the outside of the silicone tube (*external ligature*), or threaded through the inside of the tube (*occluding suture*) at the time of surgery. The purpose of the stitches is to prevent the shunt from draining excessively in the first few weeks after surgery and causing the eye pressure to be too low.

## 2. How will the shunt affect the external appearance of the eye?

### On the outside of the eye

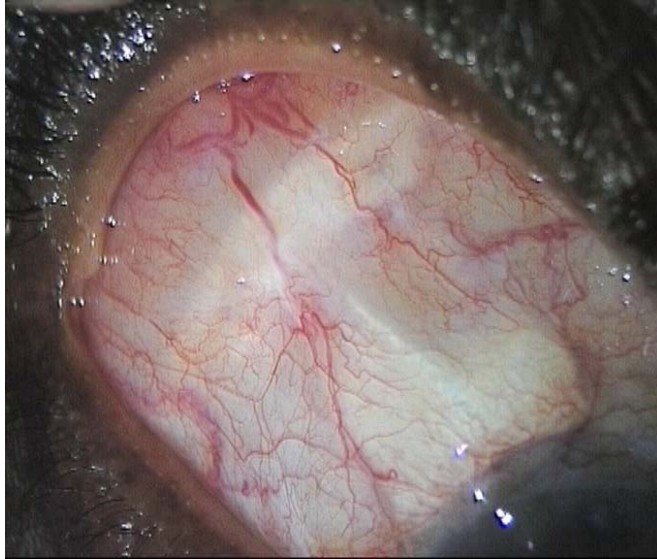
Initially after surgery the eye will be red and swollen to a variable degree. After major eye surgery the eyelid often droops. This resolves over a period of weeks to months. The aqueous shunt itself is not normally visible on the outside of the eye.

When the shunt is functioning normally, the drained fluid accumulates in a blister or *bleb* in the



**The plate portion of a shunt can be seen just underneath the eye surface when the eyelid is lifted up manually.**

conjunctiva. The plate and its bleb are positioned far back behind the eyelid so they cannot usually be seen. This fluid is slowly absorbed by the blood vessels on the eye surface. The shunt and bleb in the pictures above and below are visible only because the eyelid has been lifted up manually. Occasionally, the shunt or bleb can be seen in extremes of gaze, when the eye is looking very far down and in.

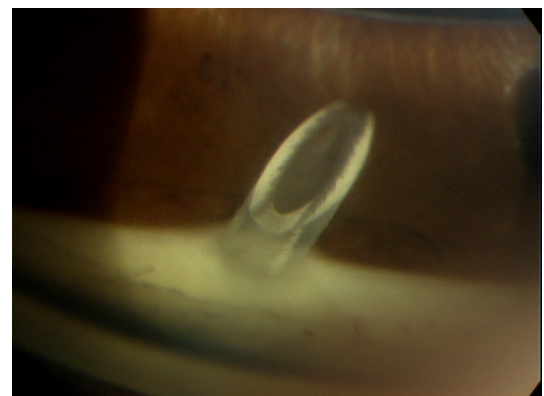


**In the example above, the shunt can be seen under the eye surface. The drainage bleb is formed just above it.**

### **On the inside of the eye**

The tube part of the shunt is placed inside the eye at the time of surgery. This is very small and cannot be seen with the naked eye. The illustrations below show the appearance of the tube when viewed at high magnification. The outside diameter of the tube part of the implant is 0.6 mm and the internal diameter, 0.3 mm. The tube itself is made of transparent silicone. The length of the tube inside the eye is usually 1 – 2 mm.

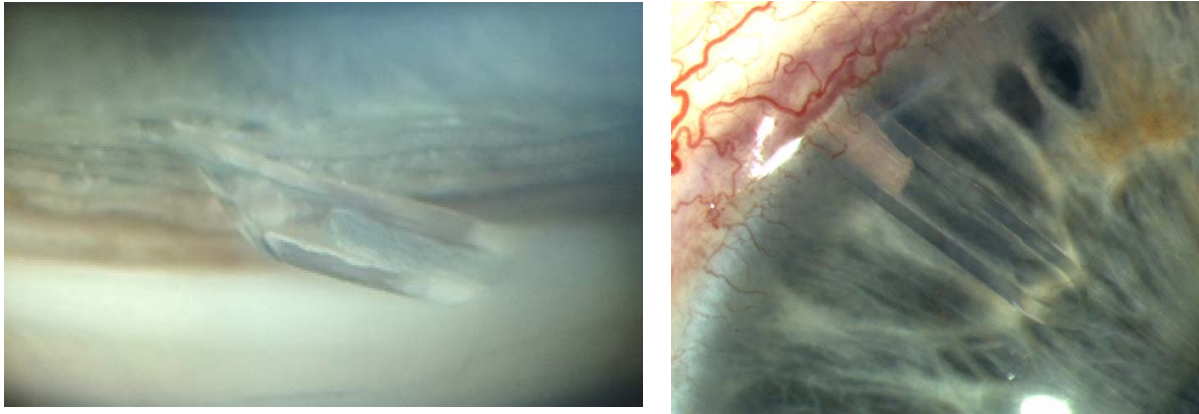
In the photograph on the right, the tube is seen entering the eye just in front of the brown iris.



In the photographs below, the tube part of the shunt can be seen just in front of the blue iris. A white nylon occluding suture

**Internal opening of the tube inside the eye**

(*Supramid*), which is used to partially obstruct the tube in order to help regulate the eye pressure, can also be seen inside the tube.



**Baerveldt tube partially obstructed by a white nylon (*Supramid*) suture inside the eye (just in front of the blue iris)**

### **3. Medication prior to surgery**

Prior to undergoing surgery, patients are asked to continue all drops and tablets in accordance with their normal treatment regimen up until the morning of the operation. Blood thinning medications such as Aspirin, Warfarin and Clopidogrel should also be continued. Patients who are taking Warfarin are advised to have their level (eg. INR) checked at least 2 weeks prior to surgery to ensure it is within the correct therapeutic range.

If patients opt to have the surgery performed under general anaesthesia, a preoperative assessment of their general health will be carried out prior to the surgery. Underlying medical conditions including cardiac disease, uncontrolled high blood pressure or diabetes will need to be addressed prior to scheduling of surgery.

### **4. The surgery itself**

Aqueous shunt surgery may last one to two hours.

#### **Anaesthesia**

Aqueous shunt implantation is often performed under general anaesthesia, although local anaesthesia is also possible under certain circumstances.

Patients who have their surgery under local anaesthesia will be awake during the operation but will have the option of requesting light sedation. The eye will be anaesthetised first with eyedrops and then an injection of anaesthetic will be administered around the eye. The anaesthetic injection itself may cause some mild discomfort; a slight sensation of pressure as the anaesthetic is delivered. The injection anaesthetises the eye, preventing not only pain but also excessive eye movement during surgery. During surgery patients are covered by a sterile sheet, or drape, which keeps the operation site sterile and also prevents patients from seeing any of the surgery. Patients will be aware of the surgeon working around the eyes, but it should not be painful. In the event of any pain or discomfort, calmly raise a hand and the surgeon will stop the surgery and top-up the anaesthetic if needed. Patients may also hear the surgeon speaking to the scrub nurse and other members of the surgical team.

### **Mitomycin C**

During the surgery, Mitomycin C may be applied to the surface of the eye for a brief period of time (up to 5 minutes). Mitomycin C is a drug that was originally used to treat cancer, but it is also used in glaucoma surgery to reduce scarring. Scarring prevents the shunt from functioning in the long term, as it prevents the aqueous humor from being absorbed back into the circulation. The Mitomycin C is then washed away from the eye with sterile water so that no residual drug remains.

### **Donor patch**

A patch made from tissue either from an eye bank (cornea or sclera) or from a commercial source (pericardium) is used to prevent break down of the conjunctival surface tissue over the shunt. If donor tissue is not used, breakdown of the conjunctival surface of the eye over the implant can occur in 10-14% of cases. When donor tissue is used the risk of breakdown is less than 3%.

The donor tissues used in aqueous shunt surgery are not live transplants. They are simply used to reinforce the eye surface over the outside of the shunt. These tissues do come from donors and are therefore tested to ensure that they cannot transmit certain infectious diseases such as Syphilis, Hepatitis B and C and HIV (the

AIDS virus). They are not, as yet, tested for prion disease (Bovine Spongiform Encephalopathy or BSE, otherwise known as mad cow disease or v-CJD) as no suitable test exists. The risk of transmission of prion disease at present appears to be extremely low.

Please note that after receiving donor tissue patients are no longer eligible to donate blood in the United Kingdom.

## **5. After surgery – post-operative care**

### **The day of surgery and the next day**

Patients are usually discharged home from hospital either the same day as the surgery or the following day. It is preferable to examine the eye again one day after surgery.

Please note; a further visit to the hospital the following day is required for those having day case surgery. Patients travelling from afar will have the option to request overnight accommodation at the time of booking the surgery.

The eye is normally padded after surgery and the eye pad is removed the following day. If the unoperated eye does not see well, then the operated eye will not be padded. Instead, a clear shield will be placed on the operated eye so that it is still possible to see after surgery.

Patients are advised to ask a friend or relative to accompany them home after surgery, especially patients who have poor sight in the unoperated eye or those who have had general anaesthesia.

### **Eye drops**

Eyedrops will be prescribed to use regularly after surgery. These are commenced on the day after surgery, after the post-operative examination. It is not usually necessary to use eyedrops the first night after the surgery. Acetazolamide (Diamox) tablets should also be stopped the night of surgery unless advised otherwise.

It is important that any eyedrops for the unoperated eye are continued unless advised otherwise.



The postoperative eyedrops will usually consist of an antibiotic (eg. *chloramphenicol*) and anti-inflammatory steroid (eg. *dexamethasone*). The steroid eye drop will initially be used intensively (every 2 hours or about 8 times daily) and the antibiotic four times daily. During the period of intensive usage preservative-free drops may be used. When drops are prescribed to take intensively after surgery, it is usually intended that they are taken during the day only. If overnight intensive use is intended, then the patient will be advised of this separately.

Patients are given a supply of postoperative eye drops on leaving the hospital; these should last one month. The postoperative eye drops will normally need to be taken for 2 to 3 months. Patients are advised at each post-operative visit whether a change in the dosage of drops is required. The drops should not be stopped or the dosage changed without consulting the doctor.

### **Postoperative clinic visits**

Patients are usually seen once a week for the first 4 weeks, and may be seen more frequently if the eye pressure is either too high or too low.

Patients who find it difficult to visit their surgeon will likely be able to alternate postoperative appointments between said surgeon and their local ophthalmologist.

### **High Pressure after surgery:**

In some cases, the ligature or occluding suture may cause high pressure after surgery. A ligature can be cut using a laser, usually 2-3 weeks after surgery at which point the pressure drops. This procedure is very quick, painless and is performed in out-patients. The occluding suture inside the tube can usually be removed after 3 months and occasionally before. The occluding suture can sometimes be removed in clinic but more often requires a return to the operating theatre to have it removed as a short operation.

It is important to note that these sutures do have an important purpose; to protect the eye from the effects of low pressure in the first few weeks after surgery. If the pressure is high in the first weeks after surgery this does not mean that the shunt

will not work, but simply that the shunt is not working yet. In such cases, it is normal for the shunt to start working after the ligature or occluding suture has been removed.

### **Low Pressure after surgery**

Sometimes the pressure may be too low after surgery and this can sometimes be dangerous. Although very low pressure is often painless, it may be associated with a dull aching feeling or a throbbing sensation within the operated eye.

Low pressure, when it occurs, is usually detected during clinic appointments and is often remedied by stopping any pressure-lowering eye drops and reducing steroid eye drops. Sometimes an injection of a jelly material (viscoelastic) is required to raise the pressure. Occasionally, a further operation is needed to reduce the drainage from the tube.

### **Activity after Surgery**

It is important to avoid strenuous activity during the early post-operative period including swimming, tennis, jogging and contact sports.

It is permissible to watch television and read, as these will not harm the eye. For patients who wish to pray, it is better to kneel but not to bow the head down to the floor in the first 2 – 3 weeks. Bending over can cause significant pain when the eye is still inflamed after surgery. Similarly, activities such as yoga that require head-down posturing should be avoided.

As patients will be monitored closely following surgery it is recommended that they consult their doctor before commencing strenuous activity. If the eye pressure is very low after surgery the doctor may suggest refraining from all exertion and remaining sedentary until the pressure is restored.

### **When can I go back to work?**

The duration of time off work will depend on a number of factors such as the nature of the patient's employment, the state of the vision in the other eye and the pressure in the operated eye.

Typically someone working in an office environment would require 2 weeks off, if the postoperative course is smooth. Someone whose occupation involves heavy manual work or work in a dusty environment may require a month or more (e.g. builders, farmers).

### **Contact lens wear after aqueous shunt implantation**

It is usually possible to restart contact lens wear around 4 weeks and sometimes sooner after aqueous shunt implantation.

### **Flying after surgery**

Although it is safe to fly after surgery, patients should bear in mind that their surgeon will wish to see them for a number of post-operative visits to ensure that the tube is functioning properly and that the eye pressure is at the correct level.

### **When is the eye back to normal?**

In most cases, it takes 2 to 3 months for the eye to feel completely normal and sometimes longer in more complicated cases. At this point the patient will usually have a refraction (spectacle) test as the spectacle prescription may have changed slightly from the pre-surgery prescription.

## **6. Success rates and complications**

### **Success rates**

Most glaucoma surgical studies examine success rates over a 5 year period. With aqueous shunts such as the *Baerveldt*, the expected success rate over 5 years is now between 70 and 80%. Although a sizeable proportion of patients achieve good pressure control without the need for continued glaucoma medication, many patients still require some medication to assist the shunt in controlling the pressure.

In such circumstances, the medication required is usually less than that required before the surgery; In one recent study using the *Baerveldt* implant the success rate after 5 years was 70% and the average patient achieved a pressure of 14.4mmHg on an average of one glaucoma eyedrop medication after 5 years.<sup>1</sup>

In a study at Moorfields eye hospital (2005) using the same implant, the average eye pressure was 11.6mmHg with only one in four patients requiring a glaucoma eyedrop medication to control the pressure by 2 years after surgery.<sup>2</sup>

Patients often ask about long term success over 10 years, 15 years or more. Because of the expense and other difficulties in performing very long-term studies, most research studies do not answer this question. Studies that have been carried out over longer periods show that most implants which are functioning successfully at 5 years continue to do so over longer periods of time.<sup>3-6</sup>

### **Complications**

Aqueous shunt surgery has become more popular as a treatment for uncontrolled glaucoma in recent years partly because of improved safety, but also because success rates have improved.

Severe complications are uncommon but are most likely to happen if the eye pressure drops very low or very quickly in the early postoperative period. A very low or an abrupt drop in eye pressure can result in a choroidal haemorrhage (severe bleeding at the back of the eye). This happens in less than 1% of aqueous shunts at Moorfields Eye Hospital. If the pressure drops very low it may be elevated again either using an injection of a viscoelastic gel or a gas into the eye in the clinic, or by a return to the operating theatre to have the tube adjusted. These interventions are only performed when the pressure is very low in order to prevent complications such as a choroidal haemorrhage, rather than waiting until after they occur.

About 5% of aqueous shunt patients at Moorfields required a return to the operating theatre in the first month after surgery for adjustment, either because of low pressure or high pressure (Moorfields Eye Hospital 2005-2006 aqueous shunt audit report, K Barton, June 2007).

The risk of serious infection inside the eye from aqueous shunt surgery at Moorfields is rare (less than 1%).

There is also a small long-term risk that the tube implant will; develop a blockage (requiring further surgery to unblock the tube); erode (the surface conjunctiva over the shunt breaks down, requiring a repair operation); or rub against the cornea requiring further surgery to either move the tube so it does not rub or, in extreme cases where significant corneal damage has occurred, a corneal transplant may be required.

## 7. References

1. Gedde SJ, Schiffman JC, Feuer WJ et al. Treatment outcomes in the Tube versus trabeculectomy (TVT) study after five years of follow-up. *Am J Ophthalmol* 2012;153:789-803.
2. Barton K. A modified stenting technique without external ligation for early flow control with the Baerveldt glaucoma drainage device. *Investigative Ophthalmology & Visual Science* . 2005.Supplement. Abstract.
3. Every SG, Molteno AC, Bevin TH, Herbison P. Long-term results of Molteno implant insertion in cases of neovascular glaucoma. *Arch Ophthalmol* 2006;124:355-60.
4. Molteno AC, Sayawat N, Herbison P. Otago glaucoma surgery outcome study : long-term results of uveitis with secondary glaucoma drained by Molteno implants. *Ophthalmology* 2001;108:605-13.
5. Molteno AC, Bevin TH, Herbison P, Houlston MJ. Otago glaucoma surgery outcome study: long-term follow-up of cases of primary glaucoma with additional risk factors drained by molteno implants. *Ophthalmology* 2001;108:2193-200.
6. Fuller JR, Bevin TH, Molteno AC. Long-term follow-up of traumatic glaucoma treated with Molteno implants. *Ophthalmology* 2001;108:1796-800.

## 8. Glossary

<b>Aqueous humor</b>	Fluid inside the front portion of the eye. This fluid is pumped into the eye by tissue called the ciliary body, and normally escapes via drainage channels called the trabecular meshwork. This fluid is completely separate from the tears and excessive tearing does not mean that the aqueous humor is draining well.
<b>Conjunctiva</b>	A thin transparent layer of skin covering the surface of the white of the eye.
<b>Cornea</b>	Transparent tissue at the front of the eye in front of the iris and lens.
<b>Intraocular pressure</b>	The pressure inside the eye. In glaucoma, high intraocular pressure is the main cause of damage to the optic nerve. This is usually measured in units known as mmHg (millimeters of mercury). In patients with normal pressure glaucoma, lowering the eye pressure still slows the disease.
<b>Optic nerve</b>	The large nerve connecting the eye to the brain. The optic nerve carries all of the visual impulses from the eye. These are then translated by the brain into the images that we see.
<b>Sclera</b>	The wall of the eyeball itself. This is seen from the front as the white of the eye.

## **9. Acknowledgements**

The author would like to thank Emma Jones, Abigail Mackrill, Rashmi Mathew, Kirithika Muthusamy, Chris Smith and Eleanor Wilkinson as well as a number of patients and their relatives for their help in the preparation of this document.

## **10. Disclaimer**

### **Accuracy**

While every step has been taken to compile accurate information and to keep it up to date, we cannot guarantee its correctness and completeness. The information provided in this information sheet is designed as an adjunct to, and not a substitute for, professional healthcare advice by a qualified doctor or other healthcare professional, which will be tailored to a patient's individual circumstances. Keith Barton and Moorfields Eye Hospital NHS Foundation Trust cannot take responsibility if patients rely solely on the information in this information sheet.

*Document Last Modified 3<sup>rd</sup> June 2013.*